

Is the Extrastriate Body Area (EBA) Sensitive to the Perception of Pain in Others?

Claus Lamm and Jean Decety

Departments of Psychology and Psychiatry and Center for Cognitive and Social Neuroscience, the University of Chicago, Chicago, IL 60637, USA

Recent neuroimaging findings suggest a role of the extrastriate body area (EBA) in self/other distinction and in the perception of pain and emotions in others. The present functional magnetic resonance imaging study investigated whether EBA is modulated by the perception of pain in others. Participants were scanned during 2 consecutive sessions: 1) a localizer task precisely identifying EBA in each individual and 2) event-related trials in which participants watched pictures of pain (needle injections into human hands) inflicted in others or control stimuli showing hands in no pain. The perception of pain recruited large parts of the so-called pain matrix, documenting shared neural representations between the perception of pain in self and other. Both the needle injections and the control stimuli consistently activated bilateral EBA, replicating involvement of this area in the perception of body parts. However, activation during the perception of painful stimuli was not different from signal changes during perception of the control stimuli. This suggests that EBA is not specifically involved in empathy for pain.

Keywords: empathy, functional MRI, localizer, neuroimaging, pain, sensory

Introduction

A number of functional neuroimaging studies in humans have identified a focal region in the extrastriate cortex that responds selectively to the visual presentation of body parts (e.g., Downing et al. 2001, 2006; Taylor et al. 2007). This region, designated the extrastriate body area (EBA), is located in the lateral occipital cortex at the posterior end of the inferior temporal sulcus. Some functional magnetic resonance imaging (fMRI) studies have found greater signal changes in the right EBA for allocentric views than for egocentric views, suggesting a role of EBA in self/other distinction (Chan et al. 2004; Saxe et al. 2006). Other studies have shown that EBA is also activated during the execution of goal-directed limb movements (Astafiev et al. 2004, 2005) and during the imitation of limb movements as compared with observation only (Jackson, Meltzoff, and Decety 2006). This might indicate that EBA is not only involved in perceptual but also in motor-related processes.

A growing body of evidence demonstrates that perceiving others in painful situations activates neural areas associated with coding the affective, motor and sensory components of the first-hand experience of pain in the observer (for recent review, Decety and Lamm 2006). Activated areas include the insula, the anterior cingulate cortex, the supplementary and cingulate motor area, and probably also the somatosensory cortex (e.g., Singer et al. 2004, 2006; Avenanti et al. 2006; Cheng et al. 2007; Gu and Han 2007; Lamm, Batson, and Decety 2007; Lamm et al. 2007; Moriguchi et al. 2007; Morrison et al. 2007). These areas belong to the pain matrix, which refers to

the central network of brain structures and pathways that process nociceptive information (e.g., Derbyshire 2000). Some of these studies as well as ongoing studies of our laboratory also have shown EBA activation during the perception of body parts in pain (e.g., Jackson et al. 2005).

An important component of pain is the preparation of skeletomotor movements of avoidance and withdrawal (Isomura and Takada 2004; Morrison et al. 2007). The consistent activation of motor structures during empathy might therefore reflect the vicarious mobilization of motor resources. In addition, there is an interesting controversy as to whether the EBA is modulated by the perception of other's emotions (e.g., Peelen and Downing 2007; Peelen et al. 2007; van de Riet et al. 2008). This raises the question whether activation of the EBA is modulated by the perception of pain in others. A mechanism underlying such a potential modulation is the allocation of attention by means of top-down control for emotionally and/or aversively evocative situations. However, a sensitive assessment of this question was precluded in former studies due to the lack of localizer runs or conditions allowing the individual functional identification of this region in each subject. Therefore, we performed a fMRI experiment that consisted of 2 parts: 1) a functional localizer task identifying EBA in each participant and 2) an event-related fMRI paradigm that presented pictures of hands in pain (with a needle injected into a finger) and of hands in no pain.

Material and Methods

Eighteen right-handed healthy volunteers (9 females) aged between 19 and 35 years (mean = 23.67 years, standard deviation = 3.99) participated in the study. All participants gave informed written consent and were paid for their participation. No subject had any history of neurological, psychiatric, or major medical disorder. The study was approved by the local Ethics Committee and conducted in accordance with the Declaration of Helsinki.

EBA was individually determined using a localizer run using the basic setup and stimuli from Paul Downing (<http://www.bangor.ac.uk/~pss811/page7/page7.html>). This run consisted of a blocked presentation of black and white photographs of chairs and bodies (without showing the head/face), with each stimulus displayed for 300 ms and a blank screen presented for 450 ms between successive stimuli. Participants performed a 1-back task requiring them to indicate by button press whenever 2 successive photographs were identical. Block and stimulus order were randomly permuted.

Following this run, participants watched photographs showing either the injection of a needle into a human hand or depicting a control stimulus where the needle was covered by a protective cap and placed next to the hand (Fig. 1). An event-related stimulus presentation mode was used, with each stimulus being displayed for 1 s, followed by a white fixation cross on black background. A total number of 36 painful and 36 nonpainful situations were presented in a pseudo-randomized sequence, with the interstimulus interval being randomly varied (mean = 3.5 s, minimum/maximum = 2/5.8 s) to reduce stimulus

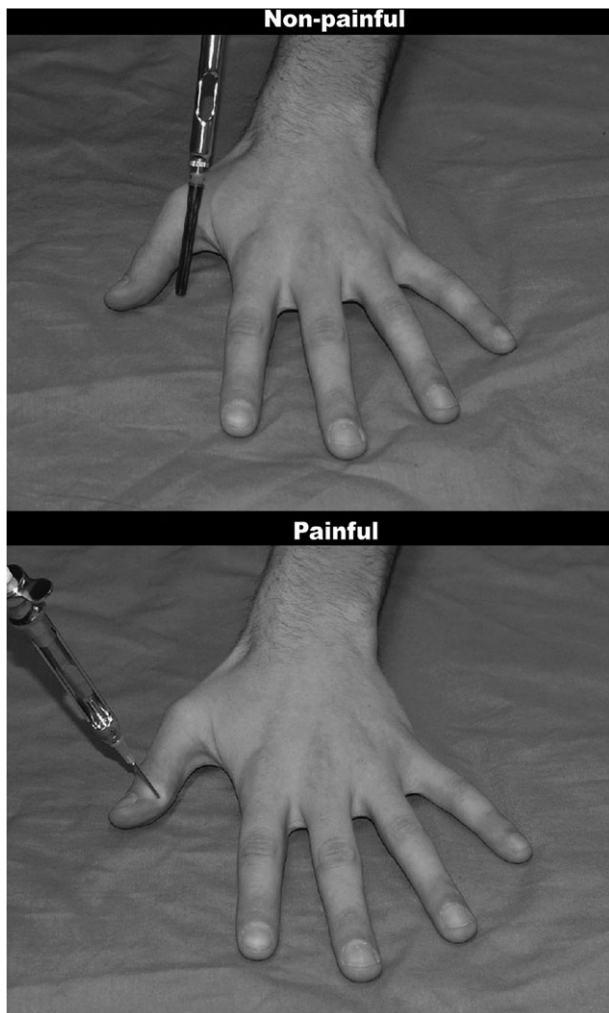


Figure 1. Sample stimuli used in the experiment.

predictability and to allow more efficient event-related signal estimation (Donaldson and Buckner 2001). All stimuli were unique shots taken from 5 different targets, with needles being injected into different parts of the hand. Injection positions and angles were varied in order to prevent habituation effects. In a similar vein, stimuli were presented in 2 runs with equal numbers of trials, with runs being separated by a short break. Needle positions and angles of the control stimuli were roughly matched to those of the injections. However, the plastic cap of the control stimuli never touched the hand and was never pointing toward it. Participants were asked to evaluate the amount of pain inflicted in the target in all trials, but actual ratings were requested only for 10 randomly selected trials per condition. The aim of these ratings was to collect behavioral data in the scanner and to ensure engagement of participants in the task. Only a subset of trials had to be evaluated in order to optimize the design for stimulus-related responses. Ratings were collected using a visual analog scale (VAS) with endpoints “no pain” (coded as 0) and “worst imaginable pain” (coded as 100). Participants used their dominant right hand to move a slider positioned on the VAS. In additional separate blocks, the same stimuli had to be evaluated for pain unpleasantness using a VAS with endpoints “not unpleasant” to “extremely unpleasant”. Because EBA responses during this type of rating were identical than during intensity ratings, we only report the latter here.

fMRI Data Acquisition and Analysis

Magnetic resonance imaging data were acquired on a 3-T head-only Siemens Magnetom Allegra System equipped with a standard quadrature

head coil. T_2^* -weighted magnetic resonance signal was measured using a single-shot echoplanar imaging (EPI) sequence (time repetition [TR] = 1810 ms, time echo = 30 ms, flip angle = 80°, 30 axial slices/volume with 4.5 mm slice thickness, in-plane resolution = 3.28 × 3.28 mm²). Each run was preceded by dummy scans ensuring steady-state magnetization conditions. A total of 500 EPI volumes was acquired in 2 separate runs for the main experiment, and 179 volumes were acquired for the EBA localizer run. Stimulus presentation and response collection were performed using the Presentation software (Neurobehavioural Systems™, Albany, CA). Visual stimuli were presented using a back-projection system, and a button box recorded the responses of subjects (entered using the dominant right hand).

Image processing was carried out using SPM2 (Wellcome Department of Imaging Neuroscience, London, UK). After preprocessing (slice-timing correction, correction for head motion, normalization to the EPI template provided in SPM2, smoothing using a 6-mm full-width half-maximum isotropic Gaussian kernel), fixed effects general linear models (GLM) were set up for each subject to model the experimental conditions (using the standard canonical hemodynamic response function as a model of hemodynamic responses; high-pass filter with a frequency cut-off at 128 s). The resulting 1st-level contrast images were entered into a 2nd-level random effects analysis assessing differences between injections and control stimuli (contrast injection > control) with population inference. This whole-brain analysis was interpreted using a voxel-level threshold of $P = 0.01$ and a spatial extent threshold of $k = 20$, corrected for multiple comparisons across the whole volume using the false discovery rate approach (Genovese et al. 2002). The choice of this threshold was determined based on previous studies on empathy for pain and on power considerations for the current paradigm (Jackson et al. 2005; Lamm and Decety 2007; Lamm, Batson, and Decety 2007; Lamm et al. 2007; Singer et al. 2004, 2006). The goal of the whole-brain analysis was to assess consistency and validity of the current results with respect to former reports investigating empathy for pain. We expected activation in various areas of the so-called pain matrix, including the anterior insula, medial and anterior cingulate cortex, inferior parietal, and ventral and dorsomedial premotor cortex.

Region-of-interest (ROI) analyses were performed using the MarsBar toolbox, v0.38 (<http://www.sourceforge.net/projects/marsbar>). The average signal of all voxels in a certain ROI was extracted for a peristimulus epoch of 15 TRs (i.e., about 27 s). ROIs for left and right EBA were defined as activity clusters in left and right lateral occipital cortices showing higher responses to images of bodies than to images of nonbodies (contrast bodies > chairs). The mean stereotactic coordinates from studies reporting EBA coordinates using a similar or the same localizer as the one we implemented were used as guidance points for localizing EBA individually (Downing et al. 2001, 2007; Astafiev et al. 2004; Peelen and Downing 2005; Saxe et al. 2006). Localization was based on visual inspection of activation maps and the identification of clusters in lateral occipitotemporal cortex close to these previously reported coordinates.

Results

Pain Ratings

Figure 2 displays the pain ratings obtained using the VAS. Ratings show that needle injections were evaluated as considerably painful for the targets and as more painful than the control stimuli which were rated as nonpainful (paired t -test, $t_{18} = 14.903$, $P < 0.001$, $\eta^2 = 0.929$). Analyzing ratings separately for the 2 imaging runs revealed that pain ratings of the 2 runs did not differ ($M = 69.71$ and $M = 69.86$ for injections, $M = 3.78$ and $M = 3.321$ for control stimuli; $F < 1$ for main effect of run and interaction run × condition, repeated measures analysis of variance).

fMRI Data—Whole-Brain Analysis

The whole-brain analysis of the contrast injections > control showed activation in large parts of the pain matrix (insula,

medial and anterior cingulate cortex, thalamus, basal ganglia, inferior parietal, supplementary motor area, dorsal and ventral premotor areas), as well as in visual areas when contrasting the 2 conditions against the fixation baseline. The whole-brain analysis also showed significant activation in bilateral lateral occipitotemporal cortices when contrasting the 2 conditions against the fixation baseline. Note though that the contrast injections > control or control > injection did not yield any significant voxels in the EBA area—even when lowering the threshold to $P = 0.1$ (uncorrected), $k = 5$, to lower the probability of false negatives (type II error). Figure 3 and Supplementary Table 1 document this activation pattern and the involved brain structures, and Supplementary Figure 1 shows activation time courses in areas of the pain matrix.

fMRI Data—EBA Analyses

The localizer run presenting images of chairs and bodies led to consistent activation in left and right EBA in all participants

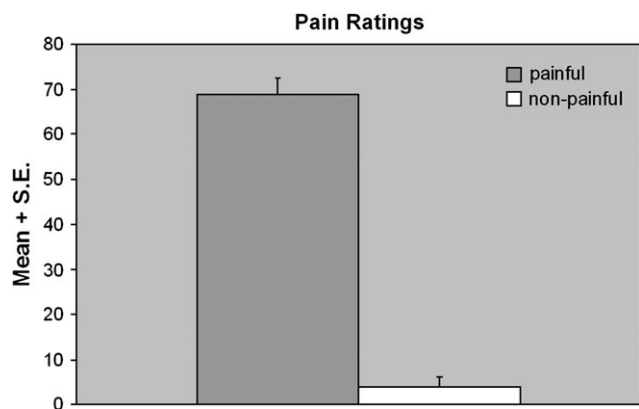


Figure 2. Pain ratings (mean + standard error) for needle injections and control stimuli.

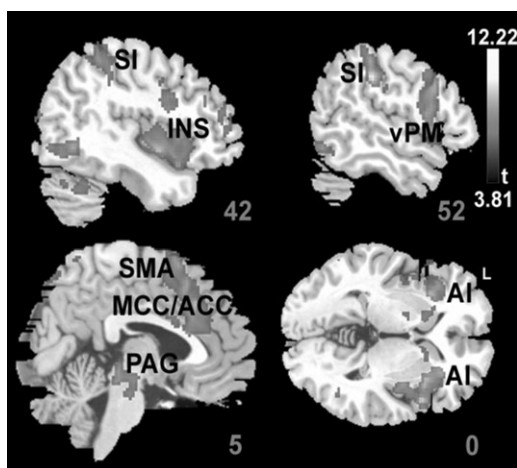


Figure 3. Whole-brain activation for the contrast injection > control. Shown are significant clusters ($P = 0.01$, $k = 20$, false discovery rate corrected) overlaid on a high-resolution structural magnetic resonance scan in Montreal Neurological Institute (MNI) space. Gray labels indicate slice number in MNI space. SI = primary somatosensory cortex, INS = insular cortex, AI = anterior insular cortex, vPM = ventral premotor cortex, SMA = supplementary motor area, MCC/ACC = medial/anterior cingulate cortex, PAG = periaqueductal gray.

(Table 1, Fig. 4). The Montreal Neurological Institute coordinates (mean [standard error]) of these cluster maxima were $x = 53.89$, $y = -66.78$, $z = 8.33$ (1.06, 1.63, 1.54) for the right EBA and -53.67 , -68.11 , 9 (1.23, 1.78, 1.34) for the left EBA—both very similar but slightly more superior as coordinates of this area reported in previous studies.

The event-related ROI analyses revealed typical hemodynamic responses triggered by the visual stimuli depicting hands (Fig. 5). Responses were not modulated by the experimental conditions, though. The main effect “condition” (painful vs. nonpainful stimuli) and the interaction term were far from being significant (all P s > 0.317). The only significant factor was time—reflecting the amplitude changes of the hemodynamic responses apparent during the chosen peristimulus analysis window (left EBA: $F_{14,238} = 17.143$, $\epsilon = 0.151$, $P_{GG} < 0.001$, $\eta^2 = 0.502$; right EBA: $F_{14,238} = 9.129$, $\epsilon = 0.129$, $P_{GG} = 0.001$, $\eta^2 = 0.349$). Linear contrasts of peak amplitudes (defined as the average signal amplitude of poststimulus TRs 3 and 4) were far from significant too (all P s > 0.26; calculated using specific error variances; Boik 1981). Additional post hoc linear contrasts

Table 1

Individual coordinates of cluster maxima in right and left EBA determined using the localizer contrast body > chairs

Subject	Left hemisphere			Right hemisphere		
	x	y	z	x	y	z
1	-50	-74	0	62	-62	12
2	-40	-80	0	50	-72	-4
3	-54	-58	16	56	-56	20
4	-52	-74	18	44	-76	16
5	-56	-64	20	54	-72	4
6	-52	-78	10	54	-76	0
7	-52	-76	4	56	-68	10
8	-56	-72	4	56	-68	4
9	-60	-56	8	56	-60	2
10	-56	-68	12	46	-72	10
11	-56	-72	8	54	-74	14
12	-62	-62	10	60	-62	2
13	-52	-72	16	52	-74	18
14	-50	-56	10	56	-62	6
15	-54	-68	10	52	-58	6
16	-50	-72	4	60	-64	10
17	-50	-68	4	50	-72	4
18	-64	-56	8	52	-54	16

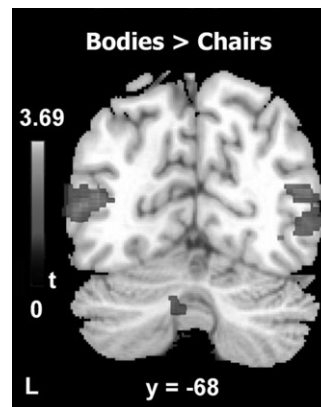


Figure 4. Activation in left and right EBA derived from the random effects contrast bodies > chairs using the EBA localizer task. Activation is thresholded at $P = 0.001$ (uncorrected), $k = 5$, and overlaid on a high-resolution magnetic resonance imaging in standard stereotactic space.

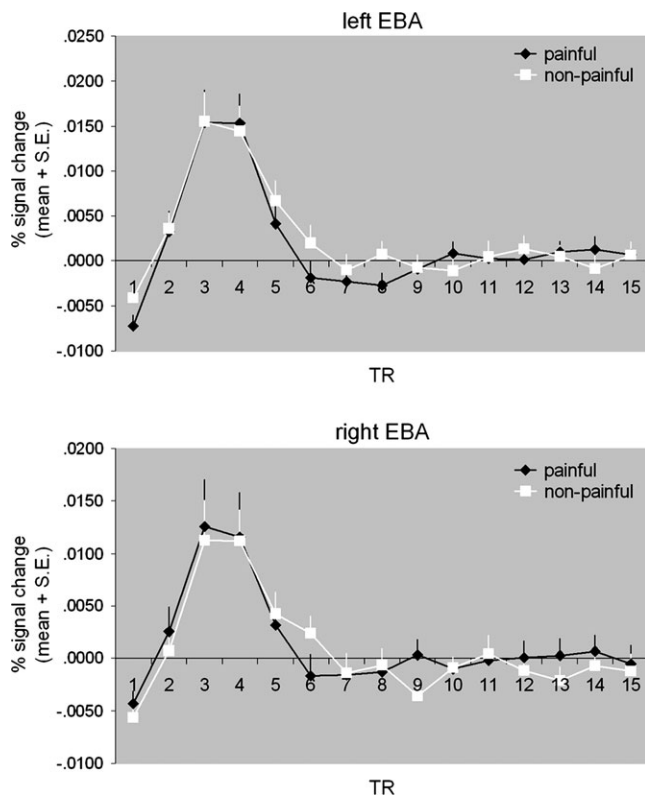


Figure 5. Event-related hemodynamic response in bilateral EBA during the perception of painful and nonpainful events. Presentation of the stimuli (at TR = 1) triggered basically identical activation changes in both hemispheres.

of data points indicating potential differences (poststimulus TRs 5–7 for left EBA, TR 6 for right EBA) revealed no significant effects either ($P = 0.371$ and $P = 0.207$, respectively).

Because some of the EBA coordinates in our sample might be considered as located more superior than previous reports, we performed an additional analysis in which we excluded participants whose EBA activation maxima were localized above a z coordinate of 10. This subanalysis revealed the same results as the analysis with the full sample ($P > 0.138$ for all analyses involving the factor condition). In addition, we correlated the peak amplitude of the contrast injection > baseline with the pain ratings and the difference in peak amplitudes of the 2 conditions with the difference in pain ratings. None of these correlations was significant (all P s > 0.188). In order to assess habituation effects, we assessed whether activation in EBA during the 1st imaging run was higher than during the 2nd one (for the contrasts injection > baseline and injection > control). No significant voxels were revealed in or around EBA, not even at a very liberal threshold of $P = 0.1$ and $k = 5$ (uncorrected for multiple comparisons).

Discussion

The goal of this study was to investigate whether EBA is sensitive to the perception of pain in others. This issue has received increased attention by recent neuroimaging results suggesting a potential contribution of EBA to self/other distinction, in particular in distinguishing whether actions are caused by oneself or by another person (e.g., Astafiev et al. 2004; David et al. 2007, 2008), as well as to the perception of emotional cues in others (Peelen and Downing 2007; van de

Riet et al. 2008). To this end, we used a well-validated paradigm to trigger empathy for pain and assessed activation in left and right EBA as individually determined using an independent functional localizer task.

As expected, the localizer task revealed consistent activation in all participants in bilateral lateral occipitotemporal cortex, confirming the sensitivity of EBA to the perception of body parts. The results also demonstrate that the perception of hands in pain was associated with reliable activation of large parts of the pain matrix, including regions involved in the affective-motivational dimension of pain processing. This finding is in line with initial fMRI reports on empathy for pain (e.g., Morrison et al. 2004; Singer et al. 2004, 2006; Jackson et al. 2005; Lamm, Batson, and Decety 2007) as well as on the anticipation of pain (Porro et al. 2004). However, our study also demonstrates that the perception of body parts in pain is associated with significant signal changes in the somatosensory cortex (Cheng et al. 2007; Lamm and Decety 2007; Lamm et al. 2007; Moriguchi et al. 2007), and thus that empathy for pain involves the somatosensory-discriminative component of the pain matrix. Altogether, the whole-brain findings are in line with theoretical views and empirical findings suggesting shared neural representations in the perception of pain in self and others (e.g., Decety and Lamm 2006; Jackson, Rainville, and Decety 2006). They also suggest that our paradigm was effective in evoking valid hemodynamic responses to the perception of pain in others.

Of special interest, although activation was found bilaterally in the EBA during the presentation of the hands, the painful situation did not result in any signal modulation in EBA. The observed event-related hemodynamic responses were virtually identical for painful and nonpainful stimuli. This was also the case when participants were asked to rate for pain affect (data not shown). Also, there was no correlation of pain ratings with signal amplitudes in EBA, and the comparison between runs suggests that the results cannot be attributed to habituation effects.

This result is important in the light of the ongoing controversy as to whether this visual region is modulated by emotional cues (Peelen and Downing 2007; van de Riet et al. 2008). One recent fMRI study demonstrated increased activation in EBA when showing short video clips of bodies expressing 5 different basic emotions (Peelen et al. 2007). However, activation increases varied across the type of emotion and were absent for sadness. In contrast, using similar stimuli, van de Riet et al. (2008) found no evidence of activation modulation in the area encompassing EBA and V5/MT. Earlier findings from de Gelder's group (e.g., de Gelder et al. 2004) also do not support a specific role of EBA when perceiving fear or happiness expressed by the whole body. Some of these discrepancies might be explained by differences in arousal and/or attention evoked by the used stimuli. However, a recent study observed no differences in EBA activation when participants watched painful (high arousal) versus nonpainful (low arousal) stimulation of what was supposedly their own hand (Lloyd et al. 2006).

Our results are in line with findings showing no modulation of EBA responses by emotional content. Note that our absence of EBA modulation cannot be attributed to a general insensitivity of the experimental design or to habituation effects. Also, although we acknowledge that the use of static stimuli may be a limitation of our design, a recent fMRI study using videos of disgusting versus painful scenes did not

observe modulation in EBA either (Benuzzi et al. 2008). We therefore suggest that activation during empathy for pain in EBA is only related to the perception of body parts and has no functional or specific relevance for the experience of empathy.

Supplementary Material

Supplementary material can be found at: <http://www.cercor.oxfordjournals.org/>.

Funding

National Science Foundation (BCS 0718480 to J.D.).

Notes

Conflict of Interest: None declared.

Address correspondence to Jean Decety, Social Cognitive Neuroscience Laboratory, Department of Psychology, The University of Chicago, 5848 S University Avenue, Chicago, IL 60637, USA. Email: decety@uchicago.edu.

References

- Astafiev SV, Stanley CM, Shulman GL, Corbetta M. 2004. Extrastriate body area in human occipital cortex responds to the performance of motor actions. *Nat Neurosci*. 7:542-548.
- Astafiev SV, Stanley CM, Shulman GL, Corbetta M. 2005. Is the extrastriate body area involved in motor actions? Reply to Peelen & Downing. *Nat Neurosci*. 8:125-126.
- Avenanti A, Paluello IM, Bufalari I, Agliotti SM. 2006. Stimulus-driven modulation of motor-evoked potentials during observation of others' pain. *Neuroimage*. 32:316-324.
- Benuzzi F, Lui F, Duzzi D, Nichelli P, Porro C. 2008. Does it look painful or disgusting? Ask your parietal cortex. *J Neurosci*. Forthcoming.
- Boik RJ. 1981. A priori tests in repeated measures designs: effects of nonsphericity. *Psychometrika*. 46:241-255.
- Chan A, Peelen M, Downing P. 2004. The effect of viewpoint on body representation in the extrastriate body area. *Neuroreport*. 15:2407-2410.
- Cheng Y, Lin C-P, Liu H-L, Hsu Y-Y, Lim K-E, Hung D, Decety J. 2007. Expertise modulates the perception of pain in others. *Curr Biol*. 17:1708-1713.
- David N, Cohen MX, Newen A, Bewernick BH, Shah NJ, Fink GR, Vogeley K. 2007. The extrastriate cortex distinguishes between the consequences of one's own and others' behavior. *Neuroimage*. 36:1004-1014.
- David N, Jansen M, Cohen MX, Osswald K, Molnar-Szakas I, Newen A, Vogeley K, Paus T. 2008. Disturbances of self-other distinction after stimulation of the extrastriate body area in the human brain. *Soc Neurosci*. Forthcoming.
- Decety J, Lamm C. 2006. Human empathy through the lens of social neuroscience. *ScientificWorldJournal*. 6:1146-1163.
- de Gelder B, Snyder J, Greve D, Gerard G, Hadjikhani N. 2004. Fear fosters flight: a mechanism for fear contagion when perceiving emotion expressed by a whole body. *Proc Natl Acad Sci USA*. 101:16701-16706.
- Derbyshire SWG. 2000. Exploring the pain "neuromatrix". *Curr Review Pain*. 4:467-477.
- Donaldson DI, Buckner RL. 2001. Effective paradigm design. In: Jezzard P, Mathews PM, Smith SM, editors. *Function MRI: an introduction to methods*. Oxford: Oxford University Press. p. 177-195.
- Downing P, Chan A, Peelen M, Dodds C, Kanwisher N. 2006. Domain specificity in visual cortex. *Cereb Cortex*. 16:1453-1461.
- Downing P, Jiang Y, Shuman M, Kanwisher N. 2001. A cortical area selective for visual processing of the human body. *Science*. 293:2470-2473.
- Downing P, Wiggett A, Peelen M. 2007. Functional magnetic resonance imaging investigation of overlapping lateral occipitotemporal activations using multi-voxel pattern analysis. *J Neurosci*. 27:226-233.
- Genovese C, Lazar N, Nichols T. 2002. Thresholding of statistical maps in functional neuroimaging using the false discovery rate. *Neuroimage*. 15:870-878.
- Gu X, Han S. 2007. Attention and reality constraints on the neural processes of empathy for pain. *Neuroimage*. 36:256-267.
- Isomura Y, Takada M. 2004. Neural mechanisms of versatile functions in primate anterior cingulate cortex. *Rev Neurosci*. 15:279-291.
- Jackson PL, Meltzoff AN, Decety J. 2005. How do we perceive the pain of others? A window into the neural processes involved in empathy. *Neuroimage*. 24:771-779.
- Jackson PL, Meltzoff AN, Decety J. 2006. Neural circuits involved in imitation and perspective-taking. *Neuroimage*. 31:429-439.
- Jackson PL, Rainville P, Decety J. 2006. To what extent do we share the pain of others? Insight from the neural bases of pain empathy. *Pain*. 125:5-9.
- Lamm C, Batson C, Decety J. 2007. The neural substrate of human empathy: effects of perspective-taking and cognitive appraisal. *J Cogn Neurosci*. 19:42-58.
- Lamm C, Decety J. 2007. The perception-action account of empathy—revisited: the contribution of shared experience to neural processing during the perception of pain in others. Poster presented at the 13th Annual Meeting of the Organization for Human Brain Mapping, Chicago, IL, June 10-14, 2007.
- Lamm C, Nusbaum HC, Meltzoff AN, Decety J. 2007. What are you feeling? Using functional magnetic resonance imaging to assess the modulation of sensory and affective responses during empathy for pain. *PLoS ONE*. 2:e1292.
- Lloyd D, Morrison I, Roberts N. 2006. Role for human posterior parietal cortex in visual processing of aversive objects in interpersonal space. *J Neurophysiol*. 95:205-214.
- Moriguchi Y, Decety J, Ohnishi T, Maeda M, Mori T, Nemoto K, Matsuda H, Komaki G. 2007. Empathy and judging other's pain: an fMRI study of alexithymia. *Cereb Cortex*. 17:2223-2234.
- Morrison I, Lloyd D, di Pellegrino G, Roberts N. 2004. Vicarious responses to pain in anterior cingulate cortex: is empathy a multisensory issue? *Cogn Affect Behav Neurosci*. 4:270-278.
- Morrison I, Peelen MV, Downing PE. 2007. The sight of other's pain modulates motor processing in human cingulate cortex. *Cereb Cortex*. 17:2214-2222.
- Peelen M, Atkinson A, Andersson F, Vuilleumier PE. 2007. Emotional modulation of body-selective visual areas. *Soc Cogn Affect Neurosci*. 2:274-283.
- Peelen M, Downing P. 2005. Within-subject reproducibility of category-specific visual activation with functional MRI. *Hum Brain Mapp*. 25:402-408.
- Peelen M, Downing P. 2007. The neural basis of visual body perception. *Nat Rev Neurosci*. 8:636-648.
- Porro CA, Lui F, Facchin F, Maieron M, Baraldi P. 2004. Percept-related activity in the human somatosensory system: functional magnetic resonance imaging studies. *Magn Reson Imaging*. 22:1539-1548.
- Saxe R, Jamal N, Powell L. 2006. My body or yours? The effect of visual perspective on cortical body representations. *Cereb Cortex*. 16:178-182.
- Singer T, Seymour B, O'Doherty J, Kaube H, Dolan RJ, Frith CD. 2004. Empathy for pain involves the affective but not the sensory components of pain. *Science*. 303:1157-1161.
- Singer T, Seymour B, O'Doherty JP, Stephan KE, Dolan RD, Frith CD. 2006. Empathic neural responses are modulated by the perceived fairness of others. *Nature*. 439:466-469.
- Taylor J, Wiggett A, Downing P. 2007. Functional MRI analysis of body and body part representations in the extrastriate and fusiform body areas. *J Neurophysiol*. 98:1626-1633.
- Van de Riet WAC, Grezes J, de Gelder B. 2008. Specific and common brain regions involved in the perception of faces and bodies and the representation of their emotional expressions. *Soc Neurosci*. Forthcoming.